



**PATIENT**

**Grayson Tonis**

**SPECIES**

Canine

**BREED**

Maltese Mix

**SEX**

Male Neutered

**AGE**

10 years

**WEIGHT**

7.44lbs

**INTERPRETED BY**

Maggie Machen  
Lamy, DVM  
DACVIM (Cardiology)

**IMAGING**

**PERFORMED BY**

Pamela Harrigan,  
RDMS

**HOSPITAL NAME**

Mass Veterinary  
Specialty Services

**REFERRING VET**

Dr. Masloski

**INVOICE**

20855

**DATE**

9/1/21

**PRESENTING CLINICAL SIGNS**

History: Recheck echo. History chronic valvular disease - Stage B2. Current presentation: Grayson is presently eating well with normal activity, no coughing and no labored breathing. CV/RESP: NSR, grade III/VI murmur with PMI left apical area radiating to right, PSS, lung fields clear. BP: 150mmHg x 5.  
-Current medications: Pimobendan/vetmedin 3.75mg 1/3 tab twice a day.  
-Pertinent previous echo findings (2/17/21 MML): LA 2.0 cm; LA:Ao 1.8; LV 2.34 cm; moderate LAE; moderate MR; trace TR (2.4 m/s). \*No sedation.

**ECHOCARDIOGRAM FINDINGS**

2D, m-mode, color flow and Doppler imaging is available.

**Left ventricle:** The LV diameter is mildly increased with adequate function. LV wall thicknesses are normal.

**Left atrium:** The left atrium is mild to moderately dilated.

**Mitral valve:** The mitral valve is thickened with prolapse into the left atrial lumen. Mild to moderate eccentric mitral regurgitation with a normal velocity.

**Aortic valve/Aorta:** The aortic valve is normal in morphology and mobility. Normal aortic outflow velocity; laminar flow. No aortic insufficiency.

**Right ventricle:** Normal right ventricular diameter and morphology indicating no overt evidence of pulmonary arterial hypertension.

**Right atrium:** Normal RA dimension.

**Tricuspid valve:** The tricuspid valve appears mildly thickened with mild tricuspid regurgitation. Velocity consistent with early PAH.

**Pulmonic valve/Pulmonary artery:** The pulmonic valve is normal in morphology and mobility. No pulmonic insufficiency. Normal RVOT velocity; laminar flow.

**Pericardium/other:** No pericardial or pleural effusion noted. No obvious cardiac masses.

**Heart rhythm:** ECG reveals a sinus rhythm with an average HR of 150bpm.

**2-Dimensional Measurements**

Ao diam (cm)	1.3
LA diam (cm)	1.8
LA:Ao (Swe)	1.4
IVS thickness (cm)	0.6
LVID diastole (cm)	2.0
PW thickness (cm)	0.7
LVID systole (cm)	0.85
FS (%)	60

**Doppler Measurements**

PV Vmax (m/s)	1.1
AoV Vmax (m/s)	1.6
MR Vmax (m/s)	5.4
TR Vmax (m/s)	3.0
TR PG (mmHg)	36

**INTERPRETATION OF THE FINDINGS**

Chronic degenerative valve disease persists with overall stability. The left heart dimensions are slightly improved, while mild PAH has developed. No additional issues are identified.



**PATIENT**  
Grayson Tonis

Given these findings, no additional medications are indicated at this time. Continued assessment of progression in the future will help predict long term outcome, which remains guarded at this stage (B2).

**SPECIES**

Canine

**BREED**

Maltese Mix

**SEX**

Male Neutered

**AGE**

10 years

**WEIGHT**

7.44lbs

**RECOMMENDATIONS**

- Continue Pimobendan lifelong.
- Omega fatty acid supplementation and mild salt restriction may be of some long-term benefit.
- Anesthetic risk is considered mild if needed. Cardiac protective drug choices (opioid/benzodiazepine premedication, propofol or alfaxalone induction, isoflurane gas) are recommended. Pre-oxygenate for 5-10 minutes prior to induction. Monitor for arrhythmias, hypotension, and hypoxia both intra and post-operatively and intervene as necessary. Mild IV fluid restriction is recommended to avoid fluid overload. Avoid heart rate stimulating drugs such as atropine unless clinically indicated.
- Monitor for development of a cough, labored breathing, exercise intolerance or collapse episodes.

**PLAN**

- Recommend conservative monitoring with a recheck echocardiogram in 6 months, sooner if any development of clinical signs.

**INTERPRETED BY**

Maggie Machen  
Lamy, DVM  
DACVIM (Cardiology)

**IMAGING  
PERFORMED BY**

Pamela Harrigan,  
RDCS

**HOSPITAL NAME**

Mass Veterinary  
Specialty Services

**REFERRING VET**

Dr. Masloski

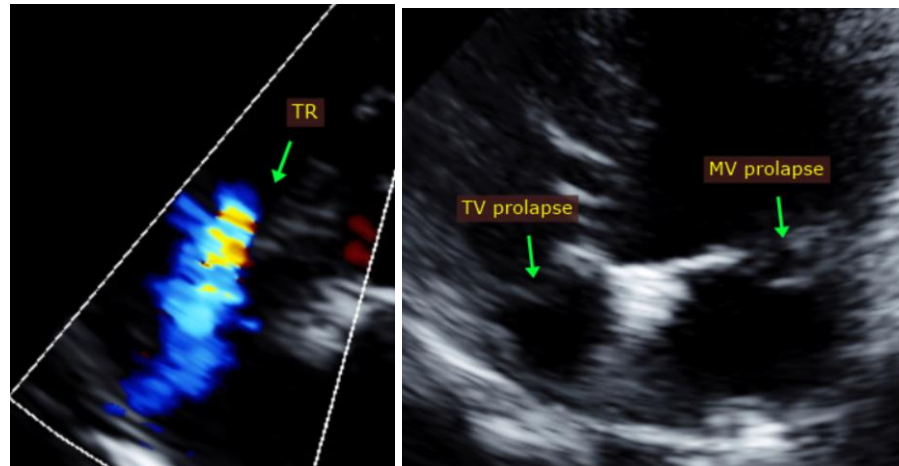
**INVOICE**

20855

**DATE**

9/1/21

**IMAGES**



**The information and recommendations provided are based on the images presented by the referring veterinarian. No evaluation can be communicated regarding pathology that was not visible in the image/video clips provided.**

Thank you for this referral. This report was generated using transcription software, and minor dictation errors may be present. If the clinical or image interpretation does not parallel your findings or if I can be of any further assistance please contact me.



**PATIENT** Maggie Machen Lamy, DVM  
**Grayson Tonis** Diplomat of the American College of Veterinary Internal Medicine (Cardiology)  
info@sonopath.com

**SPECIES** **Echocardiogram performed by:** Pamela Harrigan, RDCS  
Canine Pet Animal Ultrasound Service (4paus.com)

**BREED**  
Maltese Mix

**SEX**  
Male Neutered

**AGE**  
10 years

**WEIGHT**  
7.44lbs

**INTERPRETED BY**  
Maggie Machen  
Lamy, DVM  
DACVIM (Cardiology)

**IMAGING  
PERFORMED BY**  
Pamela Harrigan,  
RDCS

**HOSPITAL NAME**  
Mass Veterinary  
Specialty Services

**REFERRING VET**  
Dr. Masloski

**INVOICE**  
20855

**DATE**  
9/1/21